The Madras Clinical Journal

Vol. XXVIII JANUARY 1962 No. 7

CONTENTS

		Page
1.	Gynaecological and Obstetrical Emergencies in General Practice ... ... — Vishnu Sarma	199
2.	Management of Open or Compound Fractures ... — M. Natarajan	214
3.	Fracture Treatment – Combination of Western and Traditional — Shang Tien-Yu and Ku Yun-Wu	218
4.	Abstracts and Excerpts	221
5.	Association Notes	225
6.	State Secretary's Announcement	220
7.	Notes on New Products	224
8.	Announcement	226
9.	Editorial Announcement ... ... Cover	3

Introducing:

A NONSALICYLATE ANTIPYRETIC AND ANALGESIC FOR INFANTS AND CHILDREN.

PHENACIN SYRUP

Each 4 ml. (teaspoonful) contains:

N-Acetyl P. Aminophenol (Paracetamol) N. F. 0·125 Gm.

- SAFE.
- PALATABLE.
- EASE OF ADMINISTRATION.
- MAXIMUM UTILITY.
- MINIMUM INTOLERANCE.

DOSE : 1–4 years age ½ to 1 teaspoonful, 4–8 years age 1 to 2 teaspoonful, 8–12 years age 2 teaspoonful — EVERY SIX HOURS.

PACKINGS : 60 ml. Bottle, 450 ml. Bottle.

LABORATORIES ORGASYN,

43, QUEEN'S ROAD, BOMBAY-2.

ADVANCE

23 JAN 1962

FOR CIRCULATION AMONGST MEMBERS ONLY

The Madras Clinical Journal

JOURNAL OF THE MADRAS STATE BRANCH OF THE INDIAN MEDICAL ASSOCIATION
(WITH WHICH IS INCORPORATED THE "MISCELLANY")

Vol. XXVIII January 1962 No. 7

GYNAECOLOGICAL AND OBSTETRICAL EMERGENCIES IN GENERAL PRACTICE *

VISHNU SARMA, M. A. (cantab), M. D. (cantab), B. chir., M. R. C. S. (Eng.), L. R. C. P. (Lond.), D. G. O. (Madras).
Fellow, The Royal Society of Medicine, London.
Assistant Professor of Obstetrics and Gynaecology, Stanley Medical College, (The Government R. S. R. M. Lying in Hospital) Madras.

> "Much better is it often times to grow wise at home and in private than by publishing what you have amassed with infinite pains to stir up unrest that may rob you of peace and quiet for the rest of your days".

This was the conclusion of no less a person than the illustrious William Harvey, scholar of Caius college, Cambridge and of St. Bartholomew's Hospital, London, and the discoverer of that simple fact, now only too well known to every student of physiology, that blood circulates in the body. Perhaps I may take courage and publish today a few observations on gynaecological and obstetrical emergencies which one meets in practice. They may not be as important as Harvey's discovery, but are observations never the less.

Whenever a female patient presents with abdominal pain, consider the possibility that the disease most probably has something to do with her genital organs. Having decided that the disease relates to the generative tract, determine whether or not the patient is pregnant.

The most important conditions which may occur in a pregnant woman are abortion, ectopic pregnancy, rupture of the uterus and the complications of genital tract neoplasms. Of the conditions which occur in the absence of pregnancy may be included, rupture of a physiological cyst of the ovary, dysmenorrhoea, pelvic infections of varied types, endometriosis, and complications which tumours of the uterus or adnexa undergo. There are other rare conditions and we

* This was the subject of an address to the Thanjavur District Branch of the Indian Medical Association on the 15th October, 1961 at their Silver Jubilee day celebrations and later comprised into a lecture, as part of the refresher course (Obstetrics and Gynaecology) for general practitioners at Coimbatore on the 21st October, 1961.

should always be prepared for surprises; but such surprises should be rare when a proper history has been taken and the examination has been thorough. The number of diagnostic errors may still further be reduced by having recourse to such special diagnostic aids as are considered necessary.

Merely to recite to you the clinical picture of various diseases of women that present as emergencies would be to under-estimate your ability to look these up a standard book on the subject and find out for yourself. I would rather endeavour to present to you some illustrative cases where we have made a correct diagnosis and in others where we have made a mistake. However, when a mistaken diagnosis has been made, you will find it very profitable (perhaps not financially, but in the way of improving your own skill in the practice of medical art and science) to return to the operated patient and obtain a retrospective history. You will discover more often than not that there was some small point which was totally overlooked, or some vital information volunteered to you by the patient which you neither had the patience to listen to, or dismissed as being irrelevant or unimportant. It is in this way that one learns and one tries to teach; the alternative is to try and bull-doze your way with others, relying entirely on your professional seniority and power for your protection; but then you have to discard forever all claims to the pursuit of truth or knowledge.

If I were asked to fly a single seater aircraft from Madras to Delhi and I wanted advice about the flight and the hazards on the route, I would prefer to consult a navigator who has flown over this course and has at the same time been charting the course. He may have flown only a few times, but he has flown intelligently. I would rather take his advice than that of a pilot who has blindly ferried the aircraft to and fro several hundred times over the same route. In the same way, surgical experience may come by performing thousands of operations, but surgical wisdom and judgement comes finally only to those who stop to think on the way and plot the course they have followed and ask themselves, "was that correct?" and, if incorrect, "why so?".

Rupture of an ovarian follicle or corpus luteum cyst:

I had hardly embarked on my clinical studies as a student at a London hospital, when a young lady was brought in complaining of severe abdominal pain. All of us had tried to make a diagnosis and we came to the conclusion that it might be appendicitis. It was then that we decided to get the gynaecologist's opinion. He elicited an important bit of history which we had overlooked. The pain was on one side and she was in her mid-cycle. She had attacks of pain like this corresponding to the midcycle and related evidently to ovulation. Although she had evidence of peritonism, she was watched carefully and not operated upon. The young lady made a satisfactory recovery and went home. When a woman who is menstruating normally complains of lower abdominal pain on one side in her midcycle, consider the possibility of a ruptured ovarian follicle. The pain is usually sudden in onset, but may be severe. The onset of pain may be associated with slight vaginal spotting of blood. Unless intra-peritoneal haemorrhage is continuing,

the patient generally improves, and the pain diminishes. There may be no signs on pelvic examination. The clinical picture does not resemble pelvic inflammation. When rupture of an ovarian follicle is suspected, the patient may be treated conservatively. Careful observation is, however, essential and it is safer to watch the patient in a hospital where blood transfusion may be given, if it is required and even a laparotomy done when bleeding continues. At operation, local methods to ensure haemostasis from the bleeding site is to be preferred and the sacrifice of an ovary is undesirable and should be avoided at all costs. Rupture of a corpus luteum cyst presents a similar clinical picture. The pain precedes or coincides with the menstrual pain at the onset of flow. Rarely a corpus luteum cyst persists and may rupture later and closely mimic a tubal pregnancy. Here too conservative measures are to be preferred unless the surgeon's hand is forced by excessive intra-peritoneal bleeding. Local resection of the cyst is enough and healthy ovarian tissue should not be sacrificed.

Dysmenorrhoea :

The pain of dysmenorrhoea may sometimes be so severe as to mimic an intra-abdominal catastrophe. It usually occurs in young girls when ovulatory cycles are established. Anovular cycles are generally painless. Physical examination may show nothing abnormal, but that is no reason why examination should be omitted. In most cases a rectal examination suffices to exclude genital tract lesions. Diagnosis can readily be made by the fact that the pain is related to the period. The treatment of primary dysmenorrhoea is conservative and urgent surgery is not required.

Genital endometriosis :

Endometriosis may give rise to abdominal pain between one menstrual period and the next. The rupture of on ovarian endometrial cyst or of a haemetosalpinx caused by endometriosis in the tube may present an acute clinical situation in the lower abdomen simulating pelvic peritonitis, acute appendicitis, ruptured ectopic pregnancy, torsion of an ovarian cyst pedicle, or almost any other acute pelvic lesion. In such cases, pre-operative diagnosis is rarely made. Chronic lower abdominal, low back, or pelvic pain may be present continuously in advanced stages of the disease. Characteristic of intermenstrual pain of pelvic endometriosis may be such factors as increased pelvic pain on exertion or walking. Sometimes the pain is associated with a bearing down sensation or desire to defaecate, with a marked increase in the discomfort and pain as the time of menstruation approaches.

If one can be reasonably certain of the diagnosis of genital endometriosis, it may be treated conservatively; but if the rupture of a cyst causes internal bleeding and pain or otherwise is the cause of acute abdominal pain, it may be safer to look in and see.

Pregnancy :

A 29 year old patient complained of abdominal pain of a month's duration which was more severe. Further, she misled us with a history of two month's amenorrhoea. She stated she had had an abdominal operation previously, but did not know what it had been done for and she bore a right sided paramedian scar on her abdomen. She was examined by several gynæcologists and all were

of the opirion that there was a mass close to the uterus pushing the body of the uterus to the left side. In due course a laparotomy was done and a normal pregnant uterus about 20 weeks in size was discovered. There is nothing surprising about this, for the vagaries of the pregnant uterus are most unpredictable. When you add to this the vagaries of the female of our species, you can imagine how complete will be the perplexities which confront the gynæcologist in his practice. Some portions of the pregnant uterus may feel hard and others soft and the uterus may be laterally bent or inclined forwards that one may easily be misled at times by physical examination.

A 30 year old multipara complained of abdominal pain of moderate severity and a period of amenorrhoea of two months. She reported of having had *slight spotting* of blood per vagina. Three senior gynæcologists examined her and came to the conclusion that the uterus was enlarged and deflected to the right by an adnexal mass which might possibly be an ovarian tumour. In this belief she was opened up and to the surgeon's chagrin, there was a retroverted 16 weeks uterus, the seat of a normal pregnancy. There were no adnexal masses and the retroverted fundus had caused deception.

A 22 year old patient, a nullipara complained of having her periods every two to three months, but this time she presented with three months amenorrhoea and abdominal pain of moderate severity. She was seen at the end of a heavy outpatients and the cervix seemed to be pointing upwards and the uterus seemed to be enlarged to 12 weeks size. Re-examination later revealed the uterus to be separate from a soft cystic adnexal tumour of the right side. Believing it to be an ovarian cyst, she was opened up. There was a large unilocular cyst of the right ovary (probably a follicular cyst) which was readily enucleated. The left ovary had a thick capsule and beneath it several follicular cysts. This case is instructive in that a very soft ovarian cyst in close proximity to the uterus, put together with a history of amenorrhoea gave an initial impression of being a uterine pregnancy.

Another factor that sometimes causes confusion is abnormalities in formation. You may recollect how the two Mullerian ducts fuse together to form a single uterus, but there are various imperfections in fusion. Sometimes there is no fusion at all and there are two seperate uterine horns. If the uterus is made up of two partially fused horns and pregnancy enlarges one horn, it is quite easy to diagnose an ovarian tumour or other adnexal tumour complicating pregnancy. I well remember a 23 year old patient who, although married for 5 years, had never conceived. She presented to us with the complaint of vaginal bleeding which was preceded by two months of amenorrhoea. There was a hypogastric swelling just palpable which on pelvic examination gave the impression of being a bulky bicornuate uterus, but I thought the swelling was fairly firm in consistency and hence unlikely to be a pregnancy. I wrote that on the admission notes. Not withstanding this, others who examined her thought there was a moderate sized mass about 8 cms. in diameter closely adherent to the uterus and pushing it to the left side. The differential diagnosis lay between an *ectopic gestation*, *ovarian tumour* and a pelvic inflammatory mass. In

due course, the abdomen was opened and it was found that the uterus was bicornuate with a normal left horn and a pregnant right horn, the size of a 16 weeks pregnancy. The right ovary was the seat of a corpus luteum cyst and a biological test (a frog test) done in the post-operative period was positive for pregnancy. Nothing was done and the abdomen was closed.

The object of citing these cases is to impress on you that the gynæcologist should always be alive not only to pregnancy but to a pregnancy in an abnormally formed uterus.

Abortion :

Abortion is the most important cause of acute abdominal pain during pregnancy. The pain is characteristically uterine in origin. Sometimes the pain is extremely severe and in the presence of slight vaginal bleeding may lead one to suspect an ectopic pregnancy with intra-peritoneal bleeding. Pelvic examination will reveal the presence of an enlarged uterus and the soft cervix may be partially dilated. When there has been criminal interference in early pregnancy, the picture of pelvic peritonitis is added to that of abortion. The lower genital tract should be carefully visualized with a speculum to see if any injuries have been inflicted. The abortionist may perforate the uterus or even injure the bowel. In septic abortions vigorous treatment with antibiotics is most essential to bring the infection under control. As a general rule, in abortions bleeding is a more prominent symptom than abdominal pain. The opposite is the case for ectopic pregnancy.

A young woman 23 years old was pregnant for the second time. She was admitted with a history of six months amenorrhoea and vaginal bleeding of three days duration. Her general condition on examination was unsatisfactory. She had slight fever, but was delirious. The pulse was thready and of poor volume. She remained in this dangerously ill state and expired the day after admission inspite of vigorous treatment for shock and infection. Permission for a partial autopsy was obtained. She was a healthy middle aged woman. There was a large quantity of offensive yellow fluid in the peritoneal cavity. The omentum showed areas of necrosis and was adherent to the uterus and tubes in the pelvis. There were also necrotic patches on the loops of bowel lying in the pelvic cavity. The uterus was about 14 weeks size and congested and inflamed, but there was no evidence of perforation. On opening the uterine cavity, there was gross infection and a twig was lying in the cavity. The pelvic veins showed evidence of thrombo-phlebitis.

This intersting case shows that in criminal abortions a correct history is not obtained. Further, that one should be on the look out for foreign bodies that have been inserted. Lastly, we must appreciate the importance of autopsy studies to check our findings, for where there is no autopsy, clinicians lose their sense of humility and dogmatism rears its hideous head.

Pelvic inflammatory disease :

Acute pelvic inflammatory disease presents with pain in both sides of the abdomen. Tenderness is a characteristic feature. The pain is often bilateral in the early stages and subsequently spreads all over the entire lower abdomen. In acute salpingo-oophoritis, gastro-intestinal symptoms do not present unless the

patient has been ill for some time. The patient looks ill, runs a high temperature and complains of pain all over the abdomen. There may be evidence of infection in the lower genital tract. Physical examination reveals pelvic tenderness and movement of the cervix from side to side is particularly painful showing that the disease affects both tubes. In acute pelvic inflammatory disease, other conditions also have to be considered, such as the cystic ovaries of pelvic endometriosis, appendicitis or perhaps even an acute exacerbation of long standing pelvic inflammatory disease. The abdominal pain of acute appendicits begins somewhere in the region of the umbilicus and travels downwards and becomes localized in the right iliac fossa. Anorexia and nausea often precede an attack of appendicular colic. The tongue is dry. Bowel disturbances are not uncommon. It should be borne in mind that the pelvic type of appendix may very closely mimic disorders of the fallopian tube. In acute pelvic inflammatory disease, the most important part of treatment is the use of chemotherapeutic drugs and antibiotics, until the temperature has become normal and has remained like that for at least 24 hours. If there is severe peritonitis due to any cause such as acute inflammatory disease, gastro-intestinal suction may be required. Dehydration and electrolytic imbalance have to be corrected. A good history may be of considerable help, becuase pelvic inflammation often follows some operative procedure or at times attempts to induce abortion. When the acute inflammatory process subsides, an abscess may form which may subsequently rupture into the peritoneal cavity. This gives rise to lower abdominal pain of sudden onset which progresses rapidly. Generalized abdominal pain is a notable feature. The abdomen may be rigid. The patient goes into shock and sooner or later exhibits the signs of pelvic peritonitis. Where the diagnosis is in doubt, surgery may have to be undertaken, but it should be minimized. Shock requires treatment. Massive antibiotic therapy is imperative.

Ectopic pregnancy:

Writing on the acute abdomen in gynaecology, Howkins emphasizes, "any woman in her menstrual period (that is from 15 to 50 years of age) whose periods in any way depart from their normal behaviour, must be considered to be pregnant inside or outside the womb, until disproved". The correct time to diagnose tubal gestation is before rupture occurs. It is not common for the diagnosis to be made at this stage and the majority of cases are diagnosed after rupture has occured with intra-peritoneal bleeding. In the early stages, the pain is generally unilateral and referred to the affected side. Generally there is a history of an abnormal or missed period. It is not uncommon to encounter slight vaginal bleeding. Very rarely, a decidual cast may be expelled from the uterine cavity. Physical examination usually shows a bulky uterus and possibly a soft cervix. Most important of all is the presence of a very tender adnexal swelling. When intra-peritoneal bleeding has occured, the patient may complain of referred pain in the shoulders. Blood may collect in the Douglas's pouch and give rise to pelvic swelling. This swelling is exquisitely tender and has a characteristic feel on palpation when blood has begun to clot. The swelling displaces the cervix forwards so that the

cervix is pulled right under the pubic symphysis. Intra-peritoneal bleeding gives rise to the characteristic features of shock. When an ectopic pregnancy is suspected, culdocentesis is to be performed. When blood is aspirated from Douglas's pouch, one can be reasonably certain of the diagnosis. In such cases shock should be treated and an immediate laparotomy performed to control bleeding. The diseased tube should be removed.

The characteristic picture of ectopic gestation is readily recognized in the typical case, but then not a few cases are seen which are quite atypical.

A 27 year old patient complained of abdominal pain, slight blood stained discharge, difficulty in passing urine, and shoulder pain. Her periods were overdue by 38 days. She had given birth to two children. The deliveries had been natural, but the children did not survive. The last pregnancy was 13 years back. She had nausea and vomiting for 12 days and abdominal pain of a colicky nature for 10 days which was severe since 1 day. 4 years previously, she had a dilatation and curettage and other investigations to find out why she was not getting pregnant. On admission there was abdominal tenderness. Her general condition was good. The uterus was anteverted and soft and displaced to the left side. There was a fulness of the left fornix. Re-examined by another gynaecologist in the ward, the findings were confirmed, but it was thought that there was a cystic tender ovary on the left side. She was kept in the ward for several days and re-examined and then it was decided that she was not a case of ectopic and discharged; but she was readmitted a few days later with severe pain and this time a laparotomy was done to discover the presence of a tubal abortion of the left tube (Figure 1) and a large bulky ovary on the right side. That the tube was the seat of ectopic was established by histopathological study. This case shows an ectopic sometimes eludes the keen scrutiny of several gynaecologists in a specialist hospital.

Genital tract neoplasms :

Neoplasms of the genital tract rarely give rise to acute abdominal pain, but may do so when they undergo complications such as degenerative changes or torsion.

A pedunculated subserous fibromyoma of the uterus or an ovarian tumour may undergo torsion. The pain may be acute in onset, but generally remains localized over the tumour. Positive findings may be present on physical examination. Abdomino-vaginal examination may demonstrate the presence of a subserous tumour of the uterus. Torsion of or haemorrhage into a tumour may also give rise to acute abdominal pain. The diagnosis may be difficult, because the physical signs may be puzzling particularly as the omentum tends to come down and adhere to the surface of the tumour giving the impression that the tumour is larger than it really is. Tumours of the uterus and adnexae require surgical removal.

A 20 year old patient complained of lower abdominal pain and a white discharge per vaginum. Her general health, except for anaemia and slight elevation of blood pressure, was satisfactory. Examination showed the uterus to be 14 weeks in size and rather soft and an indurated mass could be felt through the right fornix. She was kept under observation in hospital. The uterus increased in size and her blood pressure remained

elevated inspite of treatment and albumin appeared in the urine. Now the diagnosis would have remained rather obscure but for a very important point in the history. Six weeks prior to admission she had been evacuated of a molar pregnancy. Two weeks after admission, she turned bad suddenly and intra-abdominal bleeding was diagnosed. Naturally internal bleeding in a patient with a vesicular mole made us think of perforation of the uterus by a mole. Laparotomy revealed the accuracy of our diagnosis (Figure 2). You may think it is a clever diagnosis, but the skill in making it lay in eliciting a history of a previous molar pregnancy. Had this history not been elicited, the diagnosis would have been puzzling. Once we knew that she had already had a mole of the uterus, the rest of the story became only too obvious. This case illustrates again how important it is to take a detailed history.

A 42 year old patient came complaining of abdominal pain. She was pregnant for the seventh time. The pain was intermittent and localized to the right iliac fossa. She gave a history of 2 months amenorrhoea. Examination showed her to be pregnant. The uterus corresponded to the period of amenorrhoea, but she had in addition a freely mobile relatively heavy tumour of the right ovary which was readily felt through the anterior fornix. These are all typical features of a "dermoid" cyst and so a plain x-ray was obtained and this showed the presence of a single tooth in the pelvis. The diagnosis was verified at operation subsequently and the tumour was removed (Fig 3). In this connection you may find it worthwhile in a case of acute abdominal pain to get a plain x-ray of the abdomen. If the patient harbours a twisted ovarian cyst and it happans to be a "deimoid", the x-ray appearances may be virtually pathognomonic.

When I was working with Dr. Horder in England, I well remember an eldeıly lady about 64 years of age who complained of abdominal discomfort which suddenly became severe. She had stopped having periods 14 years previously, but of late had slight spotting of blood. Examination showed large bilateral ovarian tumours displacing an enlarged uterus forwards. An experienced general surgeon was invited to see the case and he gave his opinion, "I think this is a very large ovarian cyst with probably haemorrhage or degeneration in it and I think she should have it operated on without scientific and deadly delay". Fine words these, for delay in an acute abdomen may be deadly and it may be better to look in and see. The diagnosis was confirmed at operation. The patient had bilateral pathogromonic solid ovarian tumours which looked congested with areas of haemorrhage. Solid ovarian tumours in postmenopausal women, especially when bilateral, should be presumed malignant until disproved and the correct treatment is total removal of the uterus and both ovaries. This was done but fortunately for the patient histopathological study showed the tumours to be benign psuedomucinous cystadenomata and the uterus contained a benign mucous polypus (Figure 4). I remember this case most vividly for another reason. The anaesthetist was a doctor from Egypt. He subsequently married the beautiful young divorced wife of ex-King Farouk, Princess Narriman Sadek. One of the elegant Egyptian silk shirts of this doctor

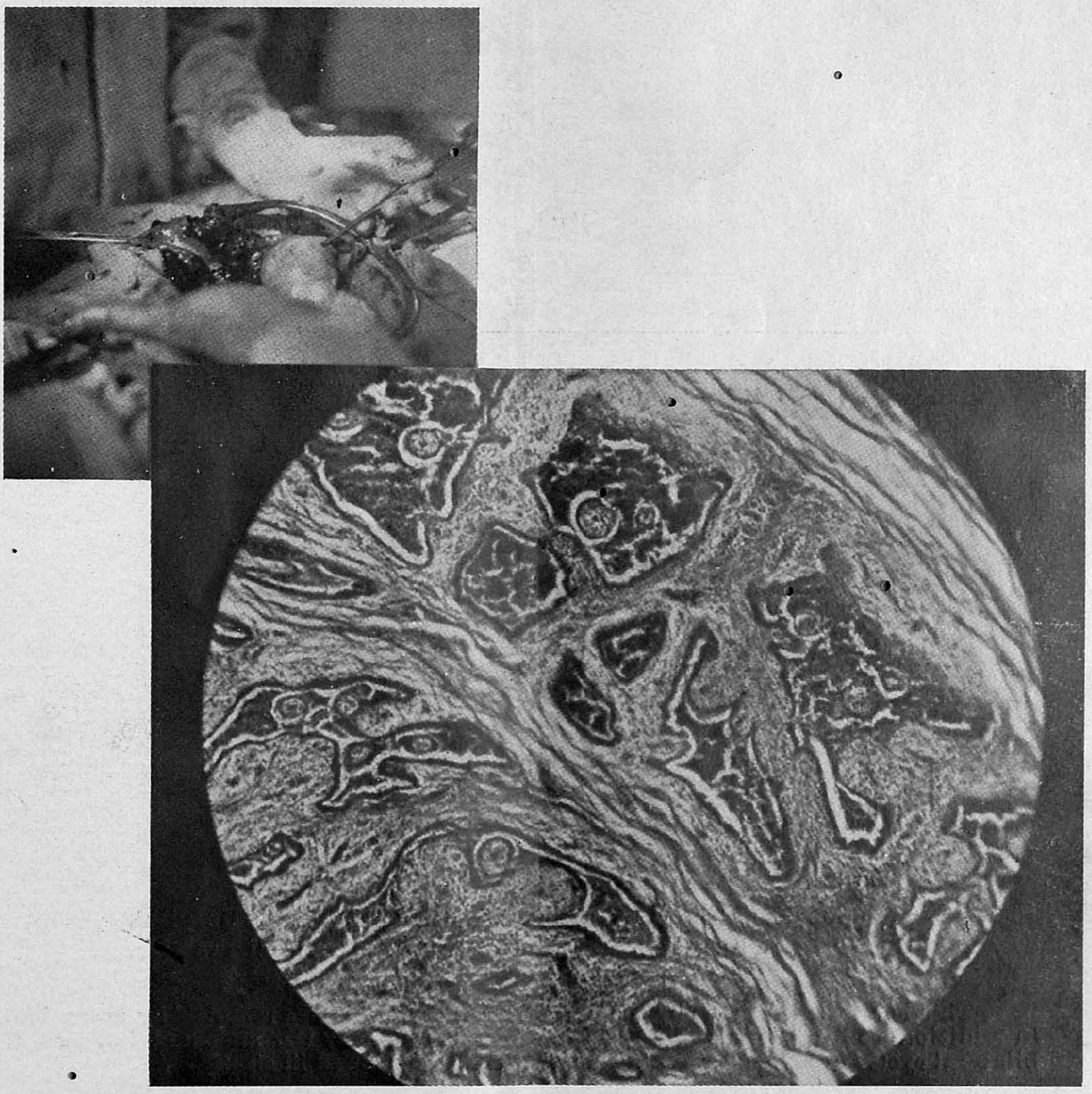

FIG 1.

(Courtesy, The Government Women and Children Hospital, Egmore, Madras).

A photograph taken at operation shows the left tube to be the seat of ectopic gestation. The blood which has escaped into the peritoneal cavity and which surrounds the tube is clearly seen. The histophotograph below depicts a haematosalpinx with chorionic villi in the blood clot. Although a clinical diagnosis can be readily made in tubal pregnancy, histopathological studies are essential to confirm pregnancy in the tube and exclude other diseases of the wall of the tube.

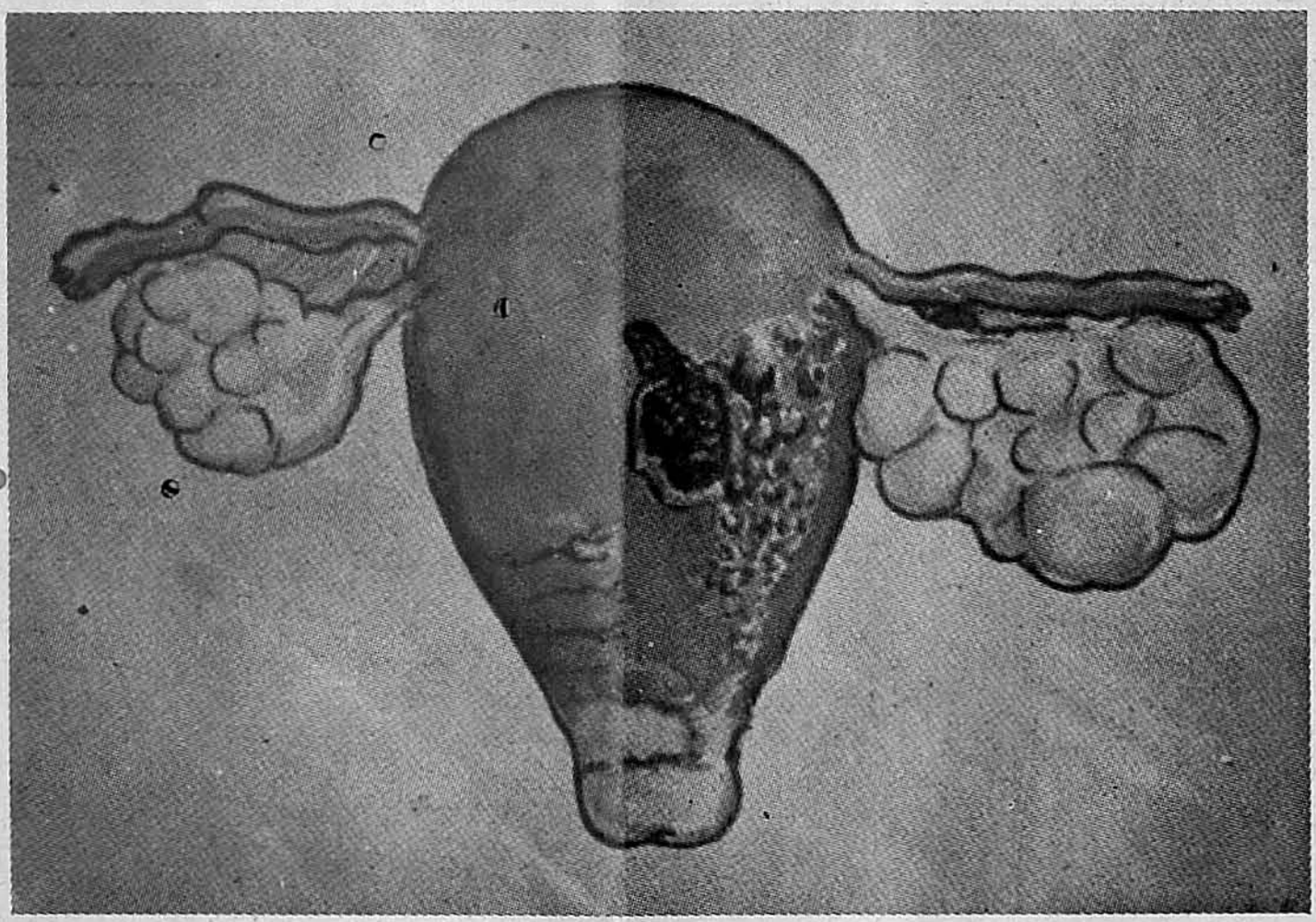

Fig. 2.

(Courtesy, The Government Women and Children Hospital, Egmore, Madras and The Editor, Current Medical Practice, Bombay.

This is a drawing made by the author shows the specimen removed by operation. In addition to the uterus which has been perforated by the mole and infiltrated, bilateral cystic ovaries are present. The uterus is enlarged in size.

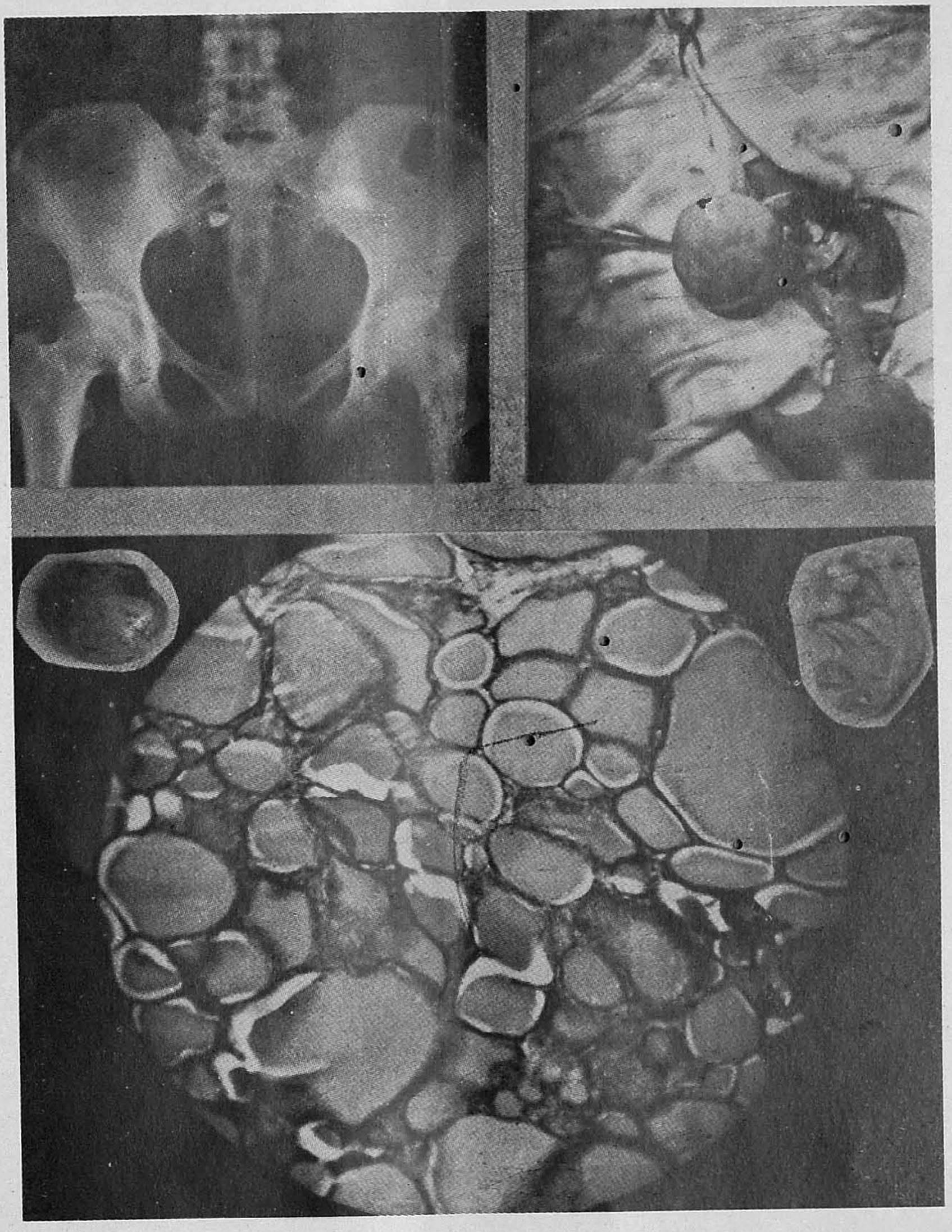

FIG. 3.

(Courtesy, The Government Women and Children Hospital, Egmore, Madras and the Editor, Surgical and Medical News).

Top Left: A plain x-ray (antero-posterior view) showing the typical calcification of a benign cystic teratoma.

Top Right: The photograph taken during the operation shows the tumour arising from the right ovary. The enlarged uterus is also towards one side. The surgeon's finger is pointing at the round ligament on the right side.

Bottom Inset Left: The external appearance of the tumour after its removal is shown. The tumour was about $2\frac{1}{2}''$ in diameter.

Bottom Inset Right: The other inset photograph shows the tumour after it was sectioned and emptied of its sebaceous contents. In its wall on the left side is seen the elevated mammilla. Two denticles are seen springing from the lower part of the mammilla. On the right side and at the top, embedded in the wall of the tumour is seen a large molar tooth with multiple cusps.

Bottom: The histo-photograph demonstrates the thyroid tissue which was present in the mammilla. There are large acini distended with colloid. All the photogrphs were taken by one of the authors (V.S.).

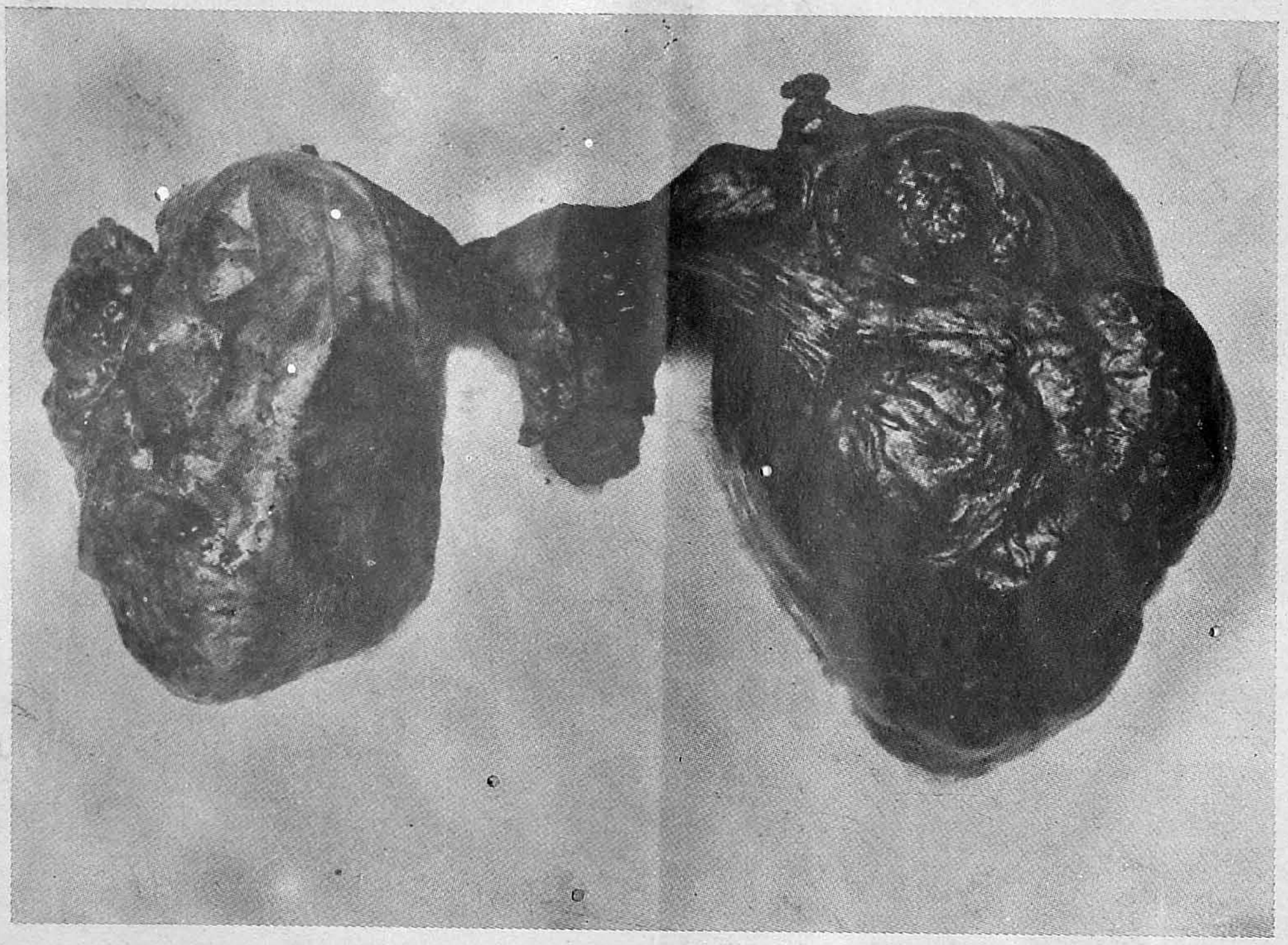

FIG. 4

FIG. 4

(Courtesy — Dr. C. H. Horder, England).

Bilateral ovarian tumours are seen with haemorrhage into the one arising from the left ovary. There was a mucous polyp within the uterine cavity. Histopathological study showed the tumours to be benign psuedomucionous cystadenomata. The polyp was benign. The patient had a total hysterectomy and bilateral salpingo-oophorectomy and made a satisfactory recovery. She was cured of her sub-acute attacks of abdominal pain.

Vishnu Sarma — *Gynaecological and Obstetrical Emergencies in General Practice.*

got mixed up with my clothes, a discovery I made only after my return to India.

Rupture of the uterus:

A 30 year old patient pregnant for the third time was admitted in a collapsed state to hospital. There had been considerable delay in the second stage and she had suddenly turned bad and she was brought in speedily. Prolonged labour with sudden deterioration of the mother's condition, especially in a multipara always makes us think of rupture of the uterus. Abdominal examination showed a full term uterus. The foetal parts were not superficial and the foetal heart was not heard. The child was presenting by the vertex and the head, although well fixed, was not engaged. The patient did not respond to resuscitative procedures including blood transfusion and died. A postmortem vaginal examination showed the cervix to be fully dilated. The vertex was presenting and there was a moderate caput. The head was jammed in the pelvis. There was no blood in the vagina. The patient's relatives agreed to have the baby removed and I had the opportunity to perform a partial autopsy. There was an incomplete rupture of the uterus and a large collection of blood seperated the two leaves of the broad ligament of the right side. There was a tear of the uterus involving the cervix. What is more, there was a large accumulation of blood in the retroperitoneal space reaching up to the right kidney and enveloping it.

Now partial autopsy is a good thing. It helps us to check our physical findings. It enables us to verify our diagnosis. It is important, if we are to improve, that we take every opportunity to look into the abdomen in cases which unfortunately die in spite of treatment; in due course, perhaps, we can also boast of an autopsy rate of at least 30 percent which the Christian Medical College at Vellore claims. Autopsy studies, even if it be only a partial study, endows us with humility apart of course from teaching us the art.

Haemorrhage, shock and sepsis are the three dangers of a ruptured uterus. By good antenatal care and good obstetric practice, one need hardly ever see a rupture. In fact, obstetricians of the West rarely see a ruptured uterus. Perhaps, that is why when he saw my photograph of a patient's abdomen whose uterus had ruptured, Dr. Greenhill of Chicago, to whom I am indebted in more than one way, accepted my picture with alacrity and published it in his latest book on obstetrics.

Accidental haemorrhage:

This is another serious complication of obstetrics and is a cause of abdominal pain in late pregnancy or in labour and requires immediate treatment. Considerable emphasis has been laid in recent times to an interesting complication of accidental hæmorrhage and that is coagulation failure.

Rupture of the spleen:

Rupture of the spleen is a rare complication of pregnancy, but cases have been reported. Usually there is a history of severe external injury or there has been some preexisting abnormality such as an enlargement due to chronic malaria. Pregnancy itself may predispose to rupture of the spleen especially in the last trimester. In the typical cases, there is localized tenderness as well as the clinical signs of intraperitoneal hæmorrhage. When intraperitoneal

hæmorrhage of sudden onset is diagnosed in a pregnant woman, one has to consider rare possibilities such as rupture of the spleen or of an aneurysm of the splenic artery. Of course, one should first consider all the more common causes of acute abdominal pain.

There are innumerable other causes of acute abdominal pain in the female. You may rarely meet such cases and even in practice in a hospital dealing exclusively with women's diseases, you may find them only occasionally. A vein on the uterine wall may rupture. A gravid uterus may become twisted. An acute haematoma may involve the rectus sheath of the abdominal wall. Urinary tract infections such as an acute pyelonephritis may cause severe acute abdominal pain. The cysterna chylii may rupture and pour chyle into the peritoneal cavity of a patient with filariasis. Acute epigastric pain may occur in pregnancy toxaemias. Diarrhoea sometimes complicates pregnancy and this cause of abdominal pain has to be evaluated. A sudden collection of fluid in the amniotic sac is also a cause of abdominal pain (acute polyhydramnios).

There are a host of other purely surgical conditions such as intestinal obstruction, appendicitis, cholecystitis, etc., which may cause pain in female and sometimes these complicate pregnancy. In tropical countries worm infestation may give rise to intestinal colic. To talk to you about these would be an unwarranted intrusion into the general surgeon's field. I would like to say this. If the specialist has someting to teach the practitioner, let it not be forgotten that the practitioner has also much to teach the specialist. It is only by sharing our experiences and our knowledge that we can benefit each other and thereby advance knowledge and progress in the art of medicine.

I have not tried to tell you about all causes of acute abdominal pain in the female whether she be pregnant or not. If I have succeeded in persuading you to think of genital tract diseases in any female patient who comes to you with abdominal pain and also to determine whether she is pregnant or not, I think I have accomplished what I set out to do this evening.

Acknowledgement :

I am grateful to Dr. V. R. Thayumanaswamy, F. R. C. S. (Eng.), M. Ch. (Ortho), Director of Medical Services, Madras for permitting me to address your association.

REFERENCES

Atlee, H. B. (1960) Acute Gynaecological and Obstetrical Emergencies, The Surgical Clinics of North America, 40, 5 : 1403.

Bailey, H. (1958) Emergency Surgery, 7th Edition, John Wright and Sons, Ltd., Bristol.

Best, B. D. (1947) The differential diagnosis of chronic lower abdominal pain in the adult female, Canad. M. A. J. 57 : 474.

Bowes, K. and Nevin, R. W. (1955) Acute abdominal conditions in pregnancy and the puerperium, Modern Trends in Obstetrics and Gynaecology, Second Series, Butterworth, London.

Bryan, W. M. (1956) Surgical emergencies in pregnancy and the puerperium, Amer. J. Obstet. Gynec. 10, 6 : 1204.

Carrington, W. J. (1945) The diagnosis of acute surgical diseases of the female pelvis and the lower abdomen, J. Amer. M. A. 128 : 434.

Greenhill, J. P. (1950) Treatment of surgical complications during pregnancy, Surgical Clinics of North America, 32 : 175.

Holland, Sir Eardley, and Bourne, Aleck, (1955) British Obstetric and Gynaecological Practice, William Heinemann Medical Books Ltd, London.

Howkins, J. (1959) The acute abdomen in Gynaecology, The Practitioner, 182 : 10 88.

Kligensmith, P. O. (1952) Acute abdominal pain of female genital origin, The Surgical Clinics of North America, 32 : 6.

Mersheimer, W. L. and Wattiker, B. J. (1960) Pregnancy complicated by acute abdominal emergencies, Clin. Obstet and Gynec, 3, 1 : 98.

Moir, Chasser, (1956) Munro Kerr's Operative Obstetrics, 6th Edition, Bailliere Tindall and Cox, London.

Montgomery, T. L. (1952) Surgical diagnostic problems in Obstetrics, The Surgical Clinics of North America, 32 : 6.

Parikh, M. N. (1959) Haemoperitoneum due to rupture of a corpus luteum, J. Obstet. Gynaec. India, 10, 2 : 197.

Pratt, J. H. (1954) Acute hemorrhagic gynecologic emergencies, The Missisippi Doctor, December : 183.

Pratt, J. H (1950) Gynecologic conditions requiring emergency surgical treatment, The J. Lancet, LXX, 6 : 203.

Pratt, J. H. and Haynes, A. L. (1955) Surgical diagnosis and treatment of acute gynecologic conditions, The J. Michigan State M. Soc. 54, February : 189.

Pratt, J. H (1947) Surgical treatment of acute gynecologic conditions, Surgical Clinics of North America, Mayo Clinic Number : 807.

Sarma, Vishnu (1955) A case of fulminating pelvic sepsis, Medical Digest, 23, 4 : 266.

Sarma, Vishnu (1957) A case of perforation of the uterus due to chorionepithelioma, Current Medical Practice, 1, 6 : 364.

Sarma, Vishnu (1955) A case of uterus bicornis unicollis with one rudimentary horn mistaken for an ovarian tumour, J. Obstet. Gynaec. India, 6, 1: 87 Reference : Masani, K. M. (1960) 3rd Edition ; Popular Book Depot : 44.

Sarma, Vishnu (1955) A classical case of tubal pregnancy, Indian Practitioner, 8, 4 : 381.

Sarma, Vishnu (with Abraham S) (1955) Axial torsion in a pseudo-mucinous cystadenoma of the left ovary, J. Indian Med. Association, 24, 12 : 470.

Sarma, Vishnu (with Kalyani E. V.) (1958) Benign cystic teratoma of the ovary complicating pregnancy, Surgical and Medical News, 4, 3 : 6.

Sarma, Vishnu (1961) Fatal complications of septic abortion. With illustrative case reports, Indian Practitioner, (In Press).

Sarma, Vishnu (1961) Gynaecological and Obstetrical Emergencies in general practice.

Sarma, Vishnu (1956) Maternal injuries, Refresher Course Series, Medical Digest, 24, 7 : 549.

Sarma, Vishnu (1959) Some surgical emergencies in Obstetrics and Gynæcology, Indian Practitioner, 12, 1 : 113.

Sarma, Vishnu (1956) The evaluation of pain in gynæcological diagnosis, Indian Practitioner, 9, 8 : 669.

Sarma, Vishnu (1959) The gastro-intestinal tract and related structures in Obstetrics and Gynæcology, The Surgical and Medical News, 5, 2 : 5 ; 5, 3 : 29 ; 5, 4 : 16 and 6, 1 : 81.

Sarma, Vishnu (1961) Gynæcological and Obstetrical aspects of Tropical diseases, Mediscope, 4, 5 : 181.

Sarma, Vishnu, (1961) The value of gynæcological knowledge in general practice, Madras Clinical Journal, 28, 2 : 37.

Sarma, Vishnu (1955) Tropical diseases in Obstetrics and Gynæcology, Medical Digest (Special number on Tropical Diseases) 23, 12 : 995 ; Obstetrical and Gynæcological Survey 1956, 11, 4 : 496.

Simpson, G. A. (1955) Abdominal aspects of gynæcology, in textbook of Surgery, Edited by Moseley, H. F. The C. V. Mosby Co. St. Louis, 2nd Edition.

Stone, M. L. and Folsome C. E. (1955) Non-obstetric surgical complications of pregnancy, The Surgical Clinics of North America, 35, 2 : 487.

Snyder, W. H. and Chaffin L. (1959) Emergency conditions in Obstetrics and General Surgery, Obstet. and Gynec. 13, 6 : 683.

MANAGEMENT OF OPEN OR COMPOUND FRACTURES

M. NATARAJAN, B. A., M. B , M. Ch. Orth., F. R. C. S. (Eng),
Professor of Orthopaedics, Madras Medical College, and Orthopaedic Surgeon,
Government General Hospital, Madras.

The incidence of serious fractures is certainly increasing due to rapid industrialisation and the greater number of traffic accidents in the roads. As these accidents can occur in any place, it is important that the doctor dealing first with these cases gives the correct type of treatment to open fractures.

A fracture is called compound or open fracture when the skin or mucous membrane overlying it is broken resulting in a communication between the fracture and the external air. The break in the covering immediately exposes the fracture to the most serious complication of fracture which is infection. In the pre-chemotherapeutic era, uncontrolled infection in a compound fracture often necessitated amputation of the limb as a life-saving measure. Even today when antibiotics are available, the improper management of an open fracture leads to chronic invalidism due to persistant infection, delayed union and non-union. The use of antibiotics can never replace good surgical attention to an open fracture.

The commonest site for a compound fracture is the tibia and fibula and that will be taken as an example to describe the management of all compound fractures.

An open fracture constitutes a surgical emergency. The need for prompt surgical care is as urgent as that for the treatment of acute abdomen.

Three primary aims should be kept in mind in planning the management of open fracture:

1. The prevention or treatment of shock to save life.
2. The prevention of infection.
3. The conversion of the open fracture into a closed fracture as early as possible.

The local treatment of a compound fracture depends on the surgical facilities available and the time after the accident the case is brought for treatment. *Contamination* of the wound is inevitable in every open fracture due to traffic or industrial accident. Any fracture which comes into the hospital 6 to 8 hours after injury must be assumed to be *infected.*

The following routine should be carried out.

Emergency care:

1. Control bleeding by pressure dressing.
2. Give morphia ¼ gr.
3. Apply an adequate splint.
4. Transport to hospital.

Hospital care:

Continue treatment of shock, administer whole blood, plasma or glucose saline as indicated. Search for evidence of other injuries, e. g. head injuries, abdominal injuries and injuries to spine. The local examination should note the state of circulation in the limb.

Types of open fracture:

Compound from within: In this the broken bone end pierces the skin and causes an open wound. This is less likely to be infected.

Compound from without: Here the open wound is caused by external violence causing laceration of wound with varying degrees of skin loss. This type is more open for contamination and infection and more foreign matter like gravel, pieces of cloth from the dress, etc. is found in the wound.

Gun-shot and shell injuries:

These are the most serious types of open fracture as the injuries to the soft tissues, muscles, vessels, tendons and nerves are more extensive and the fracture itself is badly comminuted.

When circulation is badly impaired even after shock has been overcome, it would be impossible to save the limb.

Indications for amputation:

A primary amputation should be done only when all the blood vessels have been totally severed and there is total ischemia. In the lower extremity, the amputation is best done at the site of election.

In case of the upper extremity every attempt should be made to save as much of the limb as possible. Even a part of the hand is useful as a good sensory organ. *Hence in the upper limb injuries, primary amputations should never be done* at the site of election.

Badly mutilated and crushed hand injuries are often amputated in the forearm. One must remember that the best artificial hand can never be a substitute for even a deformed hand. While a deformed hand gives an opportunity for reconstructive surgery, a primary amputation is an irrevocable step. The only indication for a proximal amputation in the upper extremity should be gas gangrene. All other injuries in the forearm and hand should be treated with conservative surgery till a final decision can be made at a later date.

When the survival of the limb is assured, our attention should be turned to the restoration of the full function and form of the limb.

Shock is first treated and the patient's general condition improved. Pressure bandage is applied over a sterile pad to stop any haemorrhage from the wound. The part is x-rayed.

The patient is then given prophylactic anti-tetanus and anti-gas gangrene sera and penicillin 500,000 units intramuscular.

Emergency surgical treatment:

The following are the essential steps of the operation:

1. General anaesthesia
2. Local preparation of the part
3. Excision of dead, devitalised and contaminated tissues and removal of foreign bodies
4. Wound irrigation
5. Haemostasis
6. Reduction of the fracture
7. Local chemotherapy
8. Closure
9. Immobilisation.

The patient is put on an operation table, the surgeon prepares himself as for a major operation. Under general anaesthesia the wound is covered

with a sterile pad and the surrounding wide area shaved and cleaned with ether soap. The limb is then draped with sterile towels.

Surgical debridement of the wound is then carried out starting from the skin edges. Remove gross dirt by flushing the wound with sterile saline. Excise a very thin (about 1 to 2 mm.) margin of skin edges. Excise the frayed edges of deep fascia.

Muscles: Remove all devitalised and dead muscle tissue till a fresh bleeding muscle is seen. This is very important as bacterial infection thrives in dead muscle tissue. All foreign bodies are removed.

Bone: Only *small* fragments of bone which are lying absolutely free should be removed. Fragments with some periosteal or soft tissue attachment should be left in position.

Tendons: Tendons which are cut should not be sutured during this procedure, but their presence should be noted and recorded.

Nerves: Nerves which are severed should not be sutured, but stitched together by a single black silk stitch.

Fracture: Now reduce the fracture and bring the fragments into good position. Apply local penicillin-sulphonamide powder.

Joint: If a joint has been opened by the wound, the capsule and the skin are closed separately after surgical flushing of the joint with sterile saline.

Closure: If the fracture has been treated within 6 – 8 hours and the wound is clean, the best procedure is to suture the wound completely. This primary closure will convert the open fracture into a closed one. The limb is immobilised in an above-knee posterior plaster slab. When the oedema has subsided after a few days, complete plaster is applied. If the wound heals by primary intention, the treatment of the fracture thereafter is that of a closed fracture.

If there is any doubt regarding the cleanliness of the wound, or if the surgical facilities of a good standard are not available, *the wound should not be sutured.* The primary wound excision as described above is done, the wound is left open, vaseline gauze is applied on the wound and sterile dressings applied over it and bandaged. The limb is given a plaster slab and the patient should be transported to a better equipped hospital or re-examined after a few days.

Delayed primary suture: After 4 or 5 days the wound is examined and if there is no infection, the wound edges are sutured. This method of closure before the wound granulates is called delayed primary suture.

Infected compound fracture: Any open fracture brought to the hospital 6-8 hours after injury should be assumed to be infected even though it appears to be clean. Some cases might be brought in with obvious infection and pus. In both these types of cases, the aim of the treatment is to provide efficient drainage for the pus. With proper drainage and antibiotics the wound infection can be cleared up.

Local treatment:

The injured limb is prepared as before and towelled. The skin wound is enlarged by extending the incisions in the long axis of the limb. The deep fascia is similarly incised. Any pocket of undrained pus or blood collection is let out. If necessary, counter incisions are made to improve drainage. After application of local chemotherapy, the wound edges are

kept apart by *loosely* filling the wound with vaseline gauze. The whole limb is encased in a complete padded plaster. In the obviously infected stage, the fracture need not be accurately reduced for the first two weeks. By this period the infection would have been under control and then the fragments could be manipulated into correct alignment and plaster applied.

Sequestrectomy : Infection in the fracture may persist due to osteomyelitis and the presence of a sequestrum. This will delay fracture union. Removal of the sequestrum will control infection and hasten the healing of the wound.

Skin grafting :

Open fractures with loss of skin do not unite until the skin cover is restored. The best time to do this is during the initial treatment of the wound itself. If a case is seen with established infection, the skin graft should be done as soon as the infection is controlled by drainage, antibiotics and removal of any sequestrum, and there is healthy granulation tissue. In places where the bone is covered by muscle and fascia, split skin graft is sufficient. In places like tibia, where the bone is superficial, a full thickness skin graft, either free or a flap pedicle graft is done to provide healthy skin over the fracture site.

Restoration of good skin cover converts the open fracture into a closed one, improves the vascularity at the fracture site and hastens union of the fracture.

Bone grafting :

In severe crush injuries or gun-shot injuries, there is often loss of a bone segment and a gap is left and such cases will end up in non-union of the fracture. After the infection is controlled and good skin cover is restored, they need a bone grafting operation to restore bone continuity and promote union of the fracture.

Physiotherapy :

Such cases of gross injury where the limb would have been immobilised for months need efficient physiotherapy to restore mobility of the joints and muscle power and restore full function in the injured limb.

Oedema and disuse are the common causes of stiffness of the feet and toes which cause difficulty in walking after a satisfactory union of the fracture. The œdema after the primary surgery must be prevented by keeping the leg elevated on pillows and asking the patient to do active movements of the toes. As soon as complete plaster is applied, the patient is taught active quadriceps contractions inside the plaster. In two weeks time the patient should be made to lift the leg in plaster off the bed and hold it up for a few seconds. This must be done atleast ten times every hour. When the fracture has united and plaster is discarded, the leg is likely to swell up. This is prevented by the application of a crepe bandage from the toes to the knee. Exercises are then given to strengthen the quadriceps muscle and mobilise the knee. This is very essential before full weight bearing is allowed.

The availability of antibiotics and improved surgical techniques have certainly improved the prognosis in open fractures. It is very important that the initial surgical care of the compound fracture is of a good standard to save many limbs and return the injured person back to useful life as early as possible.

FRACTURE TREATMENT-COMBINATION OF WESTERN AND TRADITIONAL

SHANG TIEN-YU AND KU YUN-WU

We doctors who practise western medicine in the orthopaedic department of the Tientsin People's Hospital have been studying Chinese traditional methods for treating fractures in the past two years. In the 7,000 cases treated by using a combination of western and traditional methods, a marked improvement was noted over results obtained solely by western methods. Generally speaking, fractures took only half as long to unite, the course of treatment was completed in about one-third of the time and the patients suffered much less pain.

When we started our study of traditional methods in 1958, we confined ourselves to the clinical experience of the traditional practitioners in our hospital. Large-scale research got under way in 1960 when we invited Tientsin's famous bone specialists of the traditional school to give us detailed reports on their long-standing experience. They also gave bedside lectures and demonstrations. Along with other doctors we went to Peking, Sian, Wuhan and Loyang to study the treatments used by traditional orthopaedists in those places.

Formerely we used the western "passive" treatment for fractures. After the fracture was reduced—when the bone ends were restored to the correct position by manipulation or surgery—a plaster cast which included the joints above and below the lesion was applied. This cast was not removed until the bone had united, in two or three months. During that time the patient could not move the immobilized joints.

Traditional practitioners employ both "active" and "passive" treatments. They reduce the fracture by manipulation and immobilize it by bandaging the area with paper pads and thin boards of bamboo or willow wood. As the joints above and below the fracture are not included, the limb may be moved. They lay great stress on suitable exercises for the joints and muscles so long as there is no interference with immobilization.

COMBINED TREATMENTS:

In the combined treatments, full use is made of western techniques such as anaesthesia and radiological examination, but immobilization is achieved by localized splinting. Here are some examples.

Li Tung-sheng, aged 20, came to us with a fractured forearm involving both radius and ulna bones. In such cases, reduction by manipulation is difficult and even after the arm has been put in plaster, displacement of the fracture may occur, resulting in mal-union and impaired function. Formerely, we would have operated to reduce the fracture, fastened the bone ends with steel plates or pins,

SHANG TIEN-YU is vice-head and KU YUN-WU surgeon of the orthopaedics department in the Tientsin People's Hospital.

— Courtesy : Embassy of the People's Republic of China in India.

and immobilized the arm in plaster. Surgical damage to the muscles would have been unavoidable.

Between the radius and ulna is the interossal membrane, like a tautly stratched canvas, connecting and stabilizing the bones. Surgery in the western way inevitabily damages this membrane. The traditional doctors are able to use it to assist in keeping the fracture reduced. Li's membrane had become slack after the injury, yet by applying the traditional way of manipulation, we were able to reduce the fracture very satisfactorily and the membrane regained its normal tension. A layer of paste used by traditional doctors to resorb swelling was then spread over the injured area, and the thick paper pads and splints bandaged to the forearm maintained the position of the reduced fracture. This localized splinting, though seeming to provide less tension, is more effective in maintaining fixation than the plaster cast. The adhesive nature of the paste keeps the paper pads pressed firmly against the skin, while the bandages around the splints can be adjusted to ensure immobilization, whereas the plaster cast, once the swelling is resorbed, becomes rather loose and immobilization is less effective.

After splinting the forearm, we encouraged the patient to begin gentle exercises, gradually extending the scope as the bones began to unite. At first we helped him to stretch and bend the joints of the elbow and wrist and encouraged him to use his arm muscles. Before long he could exercise the joints himself. This stimulated circulation, promoted quick growth of bone cells and speeded union. Daily massage to the injured limb repaired damaged muscles and tendons. By using the combined method, Li's arm healed in 39 days.

THE RESULTS:

When the treatment consists of plaster cast and quiet rest, not only does the fracture take at least two and a half months to heal, but the long inactivity causes stiffening of the joints, damage to the muscles and other complications. Therefore electrical treatments, massage and exercise for a further two months or so are necessary to restore function to the limb. Our combined method makes it possible for union of the fracture and restoration of function to proceed simultaneously, thus shortening the treatment and avoiding complications. In one year we treated more than 70 cases of forearm fracture and all united within six to seven weeks.

For bone fracture of the lower limbs, we use the western traction method with localized splinting to retain reduction. Li Chun-lin, 15, fell from his bicycle and broke a thigh bone. The soft tissues of the thigh are thick and the strong contractions of the muscles may cause displacement of the fracture after reduction. So we splinted Li's injured limb and put it on a traction frame After three weeks we removed the traction, but kept the limb in splints which allowed the patient to begin exercises. The fracture united in 54 days, one month sooner than would have been possible if he had been given western treatment only.

Here are some comparisons of the time required for union of several other types of fracture :

Types of Fracture	Western Treatment (average days)	Combined Treatment (average days)
Fracture of the humerus	56	28
Colle's fracture	42	28
Fracture of the tibia	130	48
Pott's fracture	56	28

We are continuing our studies clinically and experimentally; we have only made a start. Chinese medicine has a long history of treating bone fractures. The first medical work on traumatology, *Care of Bone Injuries*, appeared early in the ninth century, but records show that throughout the last 3,000 years, this branch of science steadily developed. At present orthopaedists all over the country are studying traditional treatment and combining it with western methods. Still better methods for the treatment of fractures will be worked out.

STATE SECRETARY'S ANNOUNCEMENT

At the annual meeting of the State Council of the Madras State Branch of I. M. A. held on 22—12—1961 at Vellore, the following office-bearers have been elected for the State Branch for the year 1961—'62:

Hony. State Secretary : Dr. A. Pattabi, D. M. & S., 63, Swami Naicken Street, Chintadripet, Madras-2.

Hony. Joint State Secretary : Dr. T. M. Kumaraswami, D. M. & S, L. O., 32, Thennamaram Street, Vellore, North Arcot District.

Hony. Treasurer : Dr. B. Rama Rau, B. Sc., M. B., B. S., Director, Ramarau Polyclinic, 453, Poonamallee High Road, Kilpauk, Madras-10.

By reason of the election of these new office-bearers, the office of the Madras State Branch of I. M. A. will be shifted to Madras early in January 1962, and the office will begin to function at Madras from 22—1—1962 at No. 63, Swami Naicken Street, Chintadripet, Madras-2.

All communications intended for the Madras State Branch of I. M. A. may kindly be addressed hereafter to:

"Dr. A. Pattabi, D. M. & S., Hony. State Secretary, Madras State Branch, I. M. A., 63. Swami Naicken Street, Chintadripet, Madras-2".

The retiring State Secretary takes this opportunity to thank one and all the members of I. M. A. for their help and co-operation given to him all along.

No. 2, 5th Street,
Tatabad, Coimbatore - 12.

M. P. JESUDASEN,
Retiring State Secretary.

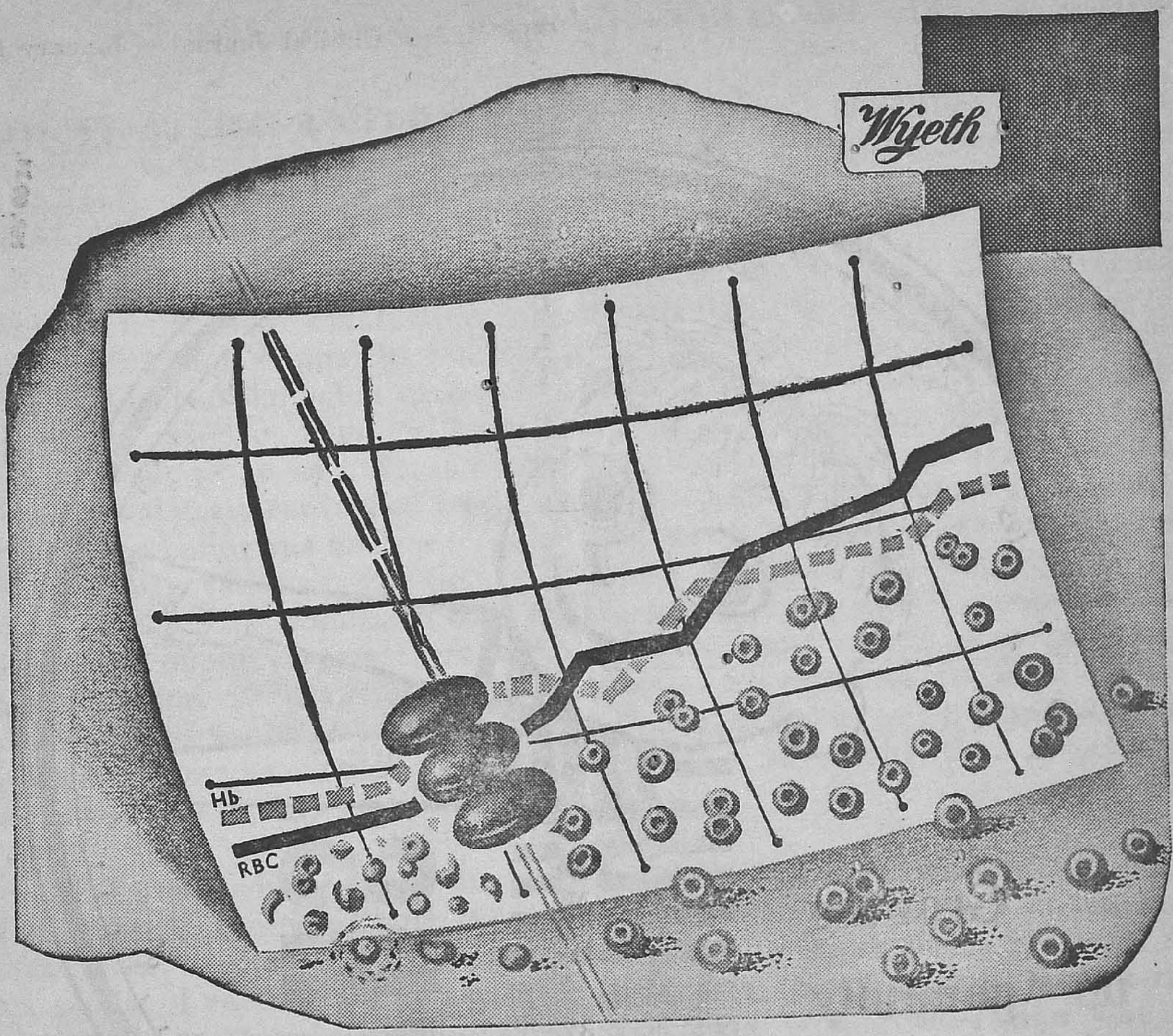

for all nutritional anaemias...

A comprehensive therapeutic formula affords the best prospect for a *prompt* and *sustained* response. Many physicians are prescribing Plastules B12 for chronic nutritional anaemias, whether "borderline" or severe, because Plastules B12 supplies:

	Per daily dose (3 capsules)
Dried Ferrous Sulphate	486 mg.
Dried Yeast	144 mg.
Folic Acid	3 mg.
Vitamin B12	15 mcg.
Liver Extract derived from 10.2 Gm. fresh liver	

PLASTULES* B12

Haematinic Compound

Supplied: *Bottles of 30 and 300 capsules*

JOHN WYETH & BROTHER LIMITED, LONDON

(Incorporated in England with Limited Liability)

Indian Branch: Steelcrete House, Dinshaw Wacha Road, Bombay I.

* Trade Mark

MP. 60.34.

SHARKOFERROL

Growing up "gainfully"

With Sharkoferrol—a well balanced general tonic with important vitamins and minerals in a palatable malt base—he grows and gains weight normally.

COMPOSITION

Each 30 ml. represents:

Vitamin A (partly from Shark Liver Oil)	*25000*	*I.U.*
Vitamin D	*5000*	*I.U.*
Saccharated Oxide of Iron	*3.55*	*Gm.*
Hypophosphites of Lime, Sodium & Potassium B.P.C.	*0.80*	*Gm.*
Vitamin B_1 B.P.	*3*	*mg.*
Vitamin B_2 *(Riboflavin)* B.P.	*2*	*mg.*
Niacinamide B.P.	*40*	*mg.*
Copper & Manganese	*traces*	
Palatable base enriched with flavoured Malt Extract	*q.s.*	

ALEMBIC
CHEMICAL WORKS
COMPANY LIMITED
BARODA-3

You can put your confidence in Alembic

ABSTRACTS AND EXCERPTS

ORAL POLIOMYELITIS VACCINE :

The reliance on safety and efficacy must rest primarily on the results obtained from the immunization of man, and there is evidence from large-scale vaccination campaigns conducted in Czechoslovakia, Mexico and the U. S. S. R. that the Sabin vaccine is safe and effective. Recently the results of an extensive campaign in Cincinnati, U. S. A., have provided additional confirmatory evidence. These conclusions, however, were not based on the results of strictly controlled trials, which are difficult to conduct successfully with living poliovirus vaccine: they are based mainly on the results of clinical surveys after vaccination, on the incidence of poliomyelitis in vaccinated groups, compared with that in appropriate control groups, and on the ability of the vaccine virus to colonize in the gut as well as to raise the level of poliomyelitis antibodies in the blood. Nevertheless in view of the overwhelming evidence from the extensive campaigns in which many millions of persons were vaccinated, it would be difficult to doubt that the Sabin oral vaccine is in fact safe and effective.

A great advantage of the oral vaccine is the ease with which it is administered, compared with the repeated injections necessary with the salk inactivated vaccine, and this undoubtedly leads to the readier acceptance by the public of vaccination by the oral preparation. In countries with large and widely scattered populations this is an important consideration, but in Britain the decision to change from inactivated to oral vaccine must rest mainly on the relative immunizing qualities of the two vaccines.

Salk vaccine has now been widely used throughout the world for six years; it has been shown to give substantial protection against poliomyelitis and has been generally accepted as a valuable prophylactic. It is evident, however, that although protection in some areas has been good, in others it has been most unsatisfactory. This is no doubt mainly due to variations of vaccine potency, associated with the difficulty of devising a biometrically sound laboratory test for antigenicity, and consequently to the lack of international agreement on an acçeptable level of antigenic potency. Sabin vaccine has also been accepted by many countries as on effective prophylactic. It has been shown to produce antibodies in a high proportion of susceptible persons either by direct vaccination or by contact with those who have been vaccinated, to boost antibody production in those who have previously received the salk vaccine, and notably to reduce the incidence of paralytic cases.

It is not possible at this stage to make a strict comparison between the two vaccines so far as their relative efficacies are concerned; longer periods of observation of the vaccinated populations are necessary, especially those who have received the oral vaccine. But there is a major point of difference in their immunizing action. Whereas the use of inactivated vaccine may lead to a substantial reduction in the incidence of poliomyelitis,

it can do little, unless of extremely high potency, to eliminate the polio virus from the gastro-intestinal tract of man. The oral vaccine, on the other hand, has the property of producing an intestinal resistance to infection, and thus when mass vaccination of a whole community is carried out over a short period of time, there is a break in the chain of transmission of polioviruses, which quickly disappear from the population. On these grounds it is argued that oral vaccination should be conducted on a community-wide basis during a period when the incidence of interfering enteroviruses is low, that it should be given to the largest possible number of persons regardless of whether they have had Salk vaccine, and that special attention should be paid to the vaccination of pre-school children, the most active spreaders of polioviruses. This procedure, in the view of those who advocate it, would eventually bring about the complete eradication of poliomyelitis as well as the causative viruses.

Oral poliomyelitis vaccine also differs from other living vaccines in its capacity to spread from vaccinated to non-vaccinated persons and in the doubtful genetic stability of the viruses used in its preparation. It is therefore of the utmost importance that careful community surveillance should be exercised when the vaccine is used for routine immunization. With proper safeguards in its manufacture and use, oral poliomyelitis vaccine offers the greatest possibility of completely eliminating poliovirus as a human pathogen.

— Editorial, British Medical Journal, July 29, 1961.

* * * *

NUTRITIONAL AND OTHER MEGALOBLASTIC ANAEMIAS AMONG AFRICANS AND INDIANS IN DURBAN:

A series of 48 African and Indian patients with megaloblastic anaemia is reviewed with particular reference to their dietary histories and serum vitamin B_{12} levels.

Most commonly megaloblastic anaemia was related to pregnancy (22 cases), a majority of these occurring within 3 months of delivery. Diets were poor in half of this group, and there was a fairly close correlation between poor diets and low serum vitamin B_{12} concentrations.

Ten patients were shown to be suffering from megaloblastic anaemia of the Addisonian type, one suffered from malabsorption, and three from cirrhosis of the liver.

By excluding known causes of megaloblastic anaemia, a group remained consisting of 11 patients all of whom had poor diets; eight of them were vegetarians. All but two of these had low serum vitamin B_{12} levels. They appear to be examples of nutritional megaloblastic anæmia.

Serum vitamin B_{12} concentrations were observed to rise during treatment with folic acid in three patients with megaloblastic anæmia of pregnancy, and in one with nutritional megaloblastic anæmia, and these findings are discussed.

— *Adams E. B., & Hift W : Transactions of the Royal Society of Tropical Medicine and Hygiene, 55, 374 - 382, 1961.*

* * * *

DIARRHOEA IN ADEN - A THERAPEUTIC TRIAL :

Two hundred and twenty-seven patients with acute diarrhoea, including 81 with bacillary dysentery, were divided into four treatment groups.

The first or empirical group was treated with an initial magnesium sulphate purge followed by chlorodyne 4 hourly for as long as it was required.

The three remaining groups were treated respectively with oxytetracycline, phthalylsulphathiazole combined with oral streptomycin and phthalylsulphathiazole alone.

The patients in whose stools no pathogens were found were treated as successfully by the empirical method alone as by the other three methods, and were in hospital approximately half the time.

Patients with bacillary dysentery were on the whole better treated with specific drugs than by the empirical method.

In the specific treatment groups there was little to choose between oxytetracycline and a combination of phthalylsulphathiazole with oral streptomycin in the treatment of patients with bacillary dysentery.

Dysentery organisms exhibited a low in vitro sensitivity to sulphonamide, and this was reflected in the less satisfactory results when these patients were treated with phthalylsulphathiazole alone.

— *Hill J. A.: Transactions of the Royal Society of Tropical Medicine and Hygiene, 55, 355 - 360 1961.*

* * * *

CIRRHOSIS OF THE LIVER IN SOUTH INDIA :

Data regarding 167 cases of cirrhosis are analysed. A high incidence is found in the 4th decade. Males predominate over females in a ratio of 3 8 : 1. There is no obvious explanation for this. Alcoholism plays an insignificant role in the etiology of the disease in S. India. The vast majority of patients coming to hospital for cirrhosis subsist on a diet which is grossly deficient in protein.

Liver cell failure with ascites and/or jaundice is the commonest mode of presentation. The average duration of symptoms before presentation to hospital is around 6 months. The most reliable biochemical test appears to be the serum electrophoretic pattern. Additional determinations of dye retention may be used if indicated. Histology shows the lesion to be postnecrotic in type. Complicating tuberculosis is very common (12.3%).

Difficulties in diagnosis are discussed, including uses of liver biopsy, and a plea is made for laparotomy in well compensated cases for the diagnosis of tuberculous peritonitis when this is suspected as a complication. Portal hypertension and massive hematemesis are relatively common. Severe hepatic insufficiency with extremely low serum albumin levels are as a rule associated and contraindicate shunt surgery. This would, therefore, seem to have little place in management.

— *Anklesaria, X. J. & Koshy, T. S. J. Ind. Med. Sciences 15, 866 - 873 1961.*

NOTES ON NEW PRODUCTS

I. Messers Chemical, Industrial and Pharmaceutical Laboratories Limited, Bombay have announced the following new products and changes in the names and compositions of some of their old products:

New Products

1. Ciplazan Tablets — Anti-filarial and anthelminthic.
2. Tolamid Tablets — For oral treatment of Diabetes Mellitus.

Change of Name:

1. Serpinoid 'Cipla' has been changed into 'Rauserpinoid'.
2. Vitmin B_{12} 'Cipla' to Ciplasmin'.

The composition and formulae of their following products have been changed and further improved:

1. Cheston 'Cipla'.
2. Alergin tablets 'Cipla'.
3. Calcima ACD tablets 'Cipla'.

II. Messers Geoffrey Manners & Company Limited, Bombay have announced their following products:

1. Vitamycetine syrup — (Chloramphenicol + Vitamins).
2. Manadol tablets — A well balanced combination of vitamins A, B Complex, C, D, E and Ferrous Fumarate.

ASSOCIATION NOTES

BRANCH NOTES

Madurai Branch:

A monthly meeting of the Madura Medical Association was held on Saturday, the 25th November, 1961, under the presidentship of Dr. K. Ramachandran, M. S., Madurai.

A resolution condemning the proposed move of 'Semi Doctors' by the Madras Government was adopted.

Dr. N. Gopinath, M.B., B.S., M. S. (Gen.), M. S. (Thor.), Thoracic Surgeon, Christian Medical College & Hospital, Vellore, gave an interesting lecture on 'Surgery in Rheumatic Diseases of the Heart'. Following this, Dr. H. T. Davenport, F. F. A. R. C. S., Professor of Anaesthesia, Children Hospital, Montreal, Canada, spoke on "Anaesthesia in Paediatric Practice".

There was an interesting film show on 'Epidural Anaesthesia' and 'Conservative Treatment of Intervertebral Disc Lesion' by Messrs Geigy, Bombay, and 'Tropical Sprue' and 'Insulins' by M/s. Burroughs Wellcome, Bombay.

Nagapattinam Branch:

A clinical meeting of the Association was held on 5—11—1961, Dr. Easwaran presiding. Dr. A. Rama Rao, B. A., L. M. & S. gave a lecture on "Exanthemata".

Nilgiris Branch:

1. At the meeting of the branch held on 13th November, 1961, Major N. R. Krishnan discussed in detail the treatment of all types of anaemias.

2. The monthly meeting of the Nilgiri Branch of I. M. A. was held at Pasteur Institute, Coonoor at 3 P. M. on Saturday the 9th December, 1961 with Dr. P. V. Kurian, the President in the chair.

Dr. K. Manonmani, M. B., B. S., Dip. Ped. (U. S. A.), Coimbatore gave an illuminating talk on 'Infant Feeding and Deficiency Diseases in Infancy and Childhood'.

A film 'Griseofulvin' kindly made available by Glaxo Laboratories (India) Ltd., Madras was projected.

Three faces wears the doctor; when first sought
An Angel's, and a God's the cure half wrought;
But when the cure complete he seeks his fee,
The Devil looks less terrible than he.

— *Unichem Medical Notes.*

ANNOUNCEMENT

A limited number of copies of the Souvenir of the 16th Madras State Medical Conference containing valuable articles on medical subjects are available to the members at a cost of Rs. 3·50 nP. inclusive of postage. Members desirous of having a copy are requested to write to Dr. T. M. Kumaraswami, 32, Thennamaram Street, Vellore, remitting Rs. 3·50 nP. by money order.

T. M. KUMARASWAMI,
Organising Secretary,
16th Madras State Medical Conference.

PLEA TO AN M. D.

The doctor is a worthy gent,
His patients claim he's heaven-sent.
The man is knowing, erudite,
But holy cats! He just can't write!

The surgeon's hands deft and skilled,
The surgeon's head is know-how filled.
Yet why – since he's so doggone bright –
Cannot the surgeon learn to write?

Dear Sons of old Hippocrates,
Pray hear a troubled nurse's pleas:
Remember that the gals in white
Have got to read the stuff you write!

Your physicals and histories,
Like Dead Sea scrolls are mysteries.
Your order sheets make nurses squint,
So please, dear Sirs, write right—
or print!

— *(J. A. M. A., Tonics and Sedatives)*

CONTROL HYPERTENSION
Successfully with
RALFEN
STANDARDIZED EXTRACT OF RAUWOLFIA SERPENTINA

★ Causes marked but gradual fall in blood pressure.
★ Lowers both systolic and diastolic pressure.
★ Relieves distressing nervous symptoms of hypertension.
★ Is a mild hypnotic and produces refreshing sleep.

Supplies:
Liquid Extract : In 28 ml. phials.
Tablet of 1·6 gm.: In bottles of fifty.

★

BENGAL CHEMICAL
CALCUTTA - BOMBAY - KANPUR

TO LET